



ELSEVIER

Contents lists available at ScienceDirect

JSES Reviews, Reports, and Techniques

journal homepage: www.jsesreviewsreportstech.org

Refractory shoulder injury related to vaccine administration: correlation with culture presence of *Cutibacterium acnes*

Kade Lyman, MD^a, Tim Kelley, MD^a, Joel Walthall, DO^a, Sarah D. Lang, MEd, ATC, OTC^b, Brian B. Gilmer, MD, FABOS^{b,*}, Dan Guttman, MD^a

^aTaos Orthopaedic Institute, Taos, NM, USA

^bMammoth Orthopedic Institute, Mammoth Hospital, Mammoth Lakes, CA, USA

ARTICLE INFO

Keywords:

SIRVA
Vaccine administration
Cutibacterium acnes
Shoulder stiffness
Shoulder inflammation
Shoulder pain

Level of evidence: Level IV; Retrospective Case Series

Background: Shoulder pain following intramuscular administration of vaccine is common. However, a small number of patients experience prolonged pain and dysfunction atypical to normal transient postvaccination shoulder pain. Shoulder Injury Related to Vaccine Administration (SIRVA) remains incompletely understood, whether a robust immune response to vaccine antigen or inappropriate injection technique with needle placement in synovial or bursal tissue, or some combination of the two. Symptoms overlap with those of *Cutibacterium acnes* (*C. acnes*) infection but the relationship between the two, if any, has not been evaluated.

Methods: Clinical case files were reviewed for 3 cases of SIRVA with positive cultures for *C. acnes* were reviewed. Presentation, treatment, and clinical outcomes were compared.

Results: In all cases, patients were thin (body mass index < 23), females, who had high injection placement of a vaccine, all patients had positive magnetic resonance imaging findings of increased signal in the subacromial bursa, and/or greater tuberosity. All patients underwent arthroscopic débridement and culture harvest and cultures were positive for *C. acnes*. A combination of oral and intravenous antibiotics was used, and all patients demonstrated clinical improvement from the preoperative state.

Discussion: This case series presents 3 patients with refractory SIRVA who ultimately underwent arthroscopic irrigation and débridement with culture biopsy. Each case had culture results positive for *C. acnes* and all responded, at least partially, to arthroscopic débridement and intravenous antibiotic therapy. The purpose of this manuscript is to raise awareness of potential coexistence of SIRVA and *C. acnes* which may be of assistance to surgeons treating refractory cases of SIRVA.

© 2023 The Authors. Published by Elsevier Inc. on behalf of American Shoulder & Elbow Surgeons. This is an open access article under the CC BY-NC-ND license (<http://creativecommons.org/licenses/by-nc-nd/4.0/>).

Shoulder pain following intramuscular administration of vaccine is common. However, a small number of patients experience prolonged pain and dysfunction out of proportion to normal transient postvaccination shoulder pain. This phenomenon now described as Shoulder Injury Related to Vaccine Administration (SIRVA) has been described in the literature.³ Although the pathophysiology of SIRVA remains incompletely understood, the presumed mechanism involves an overly robust immune response to vaccine antigen.¹⁰ Inappropriate injection technique with needle placement in synovial or bursal tissue is hypothesized to be a

contributing factor. The resulting clinical presentation includes inflammation, pain, difficulty, and often decreased range of motion.⁵ Standard treatment for SIRVA is initially conservative and supportive with oral anti-inflammatory medications, corticosteroid injections, and physical therapy forming the mainstay.¹¹ In some rare instances, arthroscopic débridement and irrigation have been required.^{9,16,18}

Currently, the incidence and prevalence of SIRVA are unknown; however, it is anticipated with the increased frequency of vaccine administration secondary to COVID-19 vaccination schedules as well as expanding indications for influenza and other vaccines; the incidence of SIRVA would be expected to increase as well. Since patients with SIRVA present with shoulder pain, it is likely these patients may present or be referred to sports medicine or shoulder specialist practices, particularly when standard conservative treatment modalities have failed.

Institutional review board approval was not required for this retrospective study.

*Corresponding author: Brian Gilmer, MD, Mammoth Orthopedic Institute, Mammoth Hospital, 85 Sierra Park Rd, PO Box 660, Mammoth Lakes, CA 93546, USA.

E-mail address: bbgilmer@gmail.com (B.B. Gilmer).

<https://doi.org/10.1016/j.xrtr.2023.02.011>

2666-6391/© 2023 The Authors. Published by Elsevier Inc. on behalf of American Shoulder & Elbow Surgeons. This is an open access article under the CC BY-NC-ND license (<http://creativecommons.org/licenses/by-nc-nd/4.0/>).

Please cite this article in press as: K. Lyman, T. Kelley, J. Walthall *et al.*, Refractory shoulder injury related to vaccine administration: correlation with culture presence of *Cutibacterium acnes*, JSES Reviews, Reports, and Techniques (2023), <https://doi.org/10.1016/j.xrtr.2023.02.011>

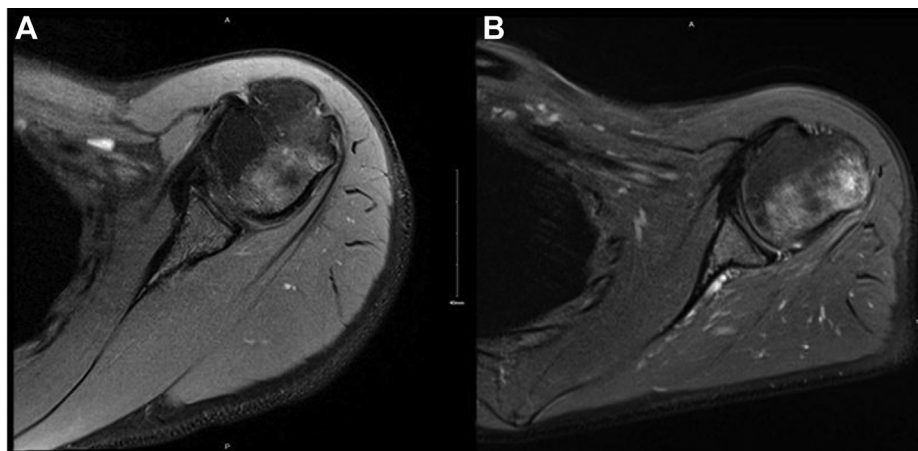


Figure 1 (A) MRI left shoulder, axial view T2 series obtained June 2018 demonstrating increased signal in the posterior aspect of the greater tuberosity with overall normal appearance of the overlying rotator cuff. (B) MRI left shoulder axial view obtained December 2018 (6 months later) demonstrating increased T2 signal in posterior greater tuberosity and involving the overlying rotator cuff and bursa. MRI, magnetic resonance imaging.

The following manuscript presents a case series of SIRVA patients with protracted shoulder symptoms who failed extensive conservative management and ultimately required operative intervention. The purpose is to provide a provisional framework for the workup and treatment of these patients and to raise the possibility of infection as a concomitant condition in the presence of refractory SIRVA.

Case 1

A 36-year-old female with no prior history of left shoulder pain reported pain and loss of function after influenza vaccination to the left shoulder. The patient had no significant prior medical history and a small body habitus (height 157.48 centimeters and weight 47.6 kilograms, calculated body mass index [BMI] of 19.2). The site of vaccine administration was described as high on the posterior deltoid.

The patient reported pain immediately following vaccination of several weeks' duration. The patient reported full range of shoulder motion but had severe limitations with overhead activities and external rotation such as buckling a seat belt or retrieving bags from the back seat of a vehicle. The patient ceased rock climbing and overhead activities requiring strength. Pain was rated 4/10 at rest and 7/10 visual analog scale (VAS) upon exertion. Single assessment numeric evaluation (SANE) score at initial presentation was 10/100.

Because of failure to improve, the patient sought medical care, an magnetic resonance imaging (MRI) was obtained approximately 4 weeks after vaccination which demonstrated increased signal in the subacromial bursa, fluid tracking along the teres minor insertion, and a superior labrum anterior to posterior lesion (Fig. 1). Conservative management was initiated with oral anti-inflammatories and physical therapy. This resulted in a decrease in symptoms at 4–8 weeks.

Unfortunately, the patient developed increasing pain and disability by 12–16 weeks. Conservative management with oral anti-inflammatories, physical therapy, and 2 corticosteroid injections provided limited relief. Approximately 16 weeks after presentation, diagnostic ultrasound was performed due to ongoing pain, which demonstrated teres minor tendinopathy and bony erosions of 3–4 mm at the teres minor insertion on the greater tuberosity of the humerus. Subsequently, repeat MRI was performed which showed increased bone marrow edema on the posterior lateral proximal humerus which correlated with the patient's area of vaccine administration (Figs. 2 and 3). Based on

continued symptoms of pain and loss of function, worsening appearance on repeat MRI, and failure of conservative measures for 6 months, the patient elected to proceed with diagnostic arthroscopy with intraoperative cultures.

Three cultures were obtained from the subacromial space: (1) subacromial aspiration was performed prior to skin incision to reduce the risk of contamination with portal creation, (2) bursal tissue was harvested with a meniscal biter from the area of greatest signal on MRI, and (3) a trephine was used to harvest greater tuberosity bone again corresponding to the area of maximal signal on MRI. Cultures were held for 21 days. One of 3 cultures returned positive for *Cutibacterium acnes* (*C. acnes*), 12 days after biopsy. The positive biopsy was from the bone sample. Concomitantly with diagnostic arthroscopy, the patient underwent extensive débridement of the subacromial space and greater tuberosity with an arthroscopic shaver and suction lavage. A total of 6 liters of saline was used during this portion of the procedure.

Postoperatively, an infectious disease consultation was obtained, and the patient ultimately underwent 6 weeks of intravenous antibiotic therapy at the recommendation of the consultant. The patient was administered Rocephin, 8 days later, had an adverse reaction, and switched to Invanz (ertapenem) for the duration (Fig. 4).

The patient experienced rapid relief of symptoms within days and progressed to near full recovery 2–3 months after arthroscopy. At final follow-up, she reported some limitations secondary to pain and weakness with rock-climbing activities and heavy lifting overhead with a SANE score of 95/100.

Case 2

A 27-year-old female received a Tetanus, Diphtheria, and Pertussis vaccine to the left shoulder in July 2020 at a primary care office. She similarly had a small body habitus (height 157.48 centimeters, weight 56.7 kilograms, calculated BMI 22.9). The patient developed increasing left shoulder pain starting 12–24 hours following the injection. The patient reported the pain was worse with shoulder movement and was worse at night with preserved range of motion. Pain was worse with overhead activities including putting on a shirt. She first sought medical care for the left shoulder 8 days following the injection. SANE score at initial presentation was 10/100. The site of vaccine administration was described as high and posterior.

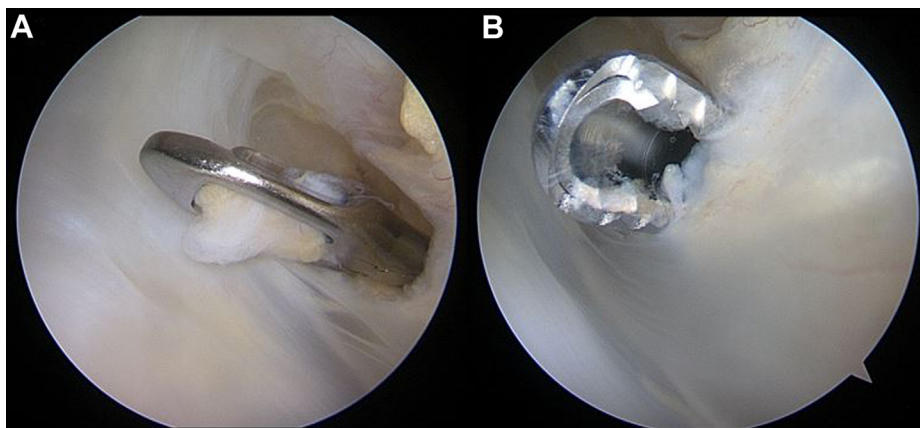


Figure 2 Left shoulder beach chair posterior viewing portal 3 demonstrating the subacromial space. (A) A meniscal punch is used to harvest tissue sample for culture. (B) Arthroscopic shaver performing subacromial bursectomy and débridement.

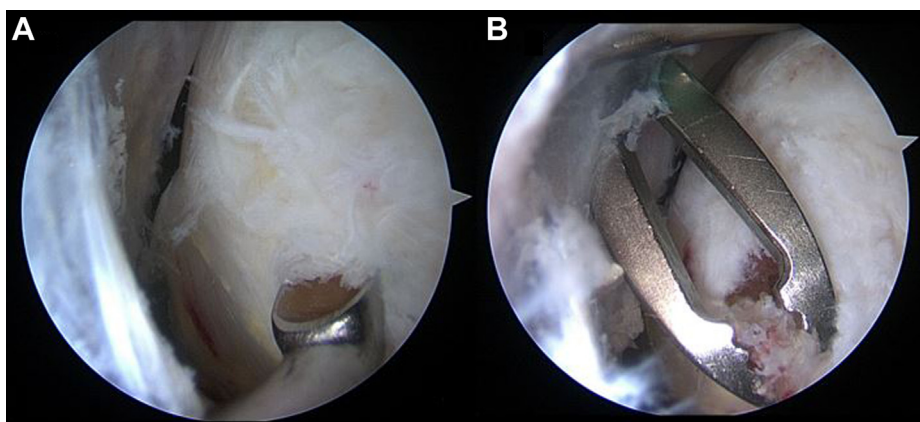


Figure 3 Left shoulder arthroscopic view of left shoulder with the 30-degree arthroscope in the anterior lateral portal viewing posteriorly towards the posterior greater tuberosity. (A) Curette creating a bone fragment for culture harvest. (B) Arthroscopic grasper is removing a bone fragment for culture.

Due to atypical presentation and failure to respond to initial conservative measures, an MRI was obtained 14 days after injection and was concerning for nonspecific synovitis. The patient was then prescribed opioids and physical therapy without clinical improvement.

Eight weeks after the vaccine injection, the patient had worsening shoulder pain rated 10/10 VAS and developed concomitant fevers and chills with generalized malaise. A glenohumeral joint aspiration was performed and the white blood cell count was consistent with septic arthritis > 60,000.

The following day, the patient underwent arthroscopic irrigation and débridement of the shoulder. Fluid aspiration from the glenohumeral joint and tissue biopsies from the glenohumeral joint obtained with a meniscal punch were positive for *C. acnes*. Arthroscopic extensive débridement of the shoulder was performed with synovectomy performed with an arthroscopic shaver of the glenohumeral joint and débridement of the subacromial space.

Postoperatively, the infectious disease service was consulted and recommended 6 weeks of intravenous antibiotic therapy. Physical therapy was initiated without restriction to facilitate return of shoulder motion and strength. The patient noted relief approximately 8 days after surgery. At final follow-up,

approximately 14 months after inoculation and 12 months after arthroscopic débridement, the patient reported a SANE score of 75/100 with complaints of persistent pain (4/10 VAS with activity) and weakness with overhead activities and most forms of upper body exercise.

Case 3

A 33-year-old female received an influenza vaccine to the left shoulder at an urgent care office in September 2020. The patient reported immediate and increasing left shoulder pain following the injection. She reported activity-related pain and night pain without fevers or chills. The patient had no prior medical history, no prior history of shoulder complaints, and had a small body habitus (height 165.1 centimeters, weight 61.23 kilograms, calculated BMI 22.5). Injection location was described as “very high at the edge of the bone on top of my shoulder.”

This patient first sought medical care for her increasing shoulder pain 4 days following her vaccination. After a period of observation and reassurance, there was no improvement and patient eventually presented to a surgical office. At presentation, pain was rated as 8–9/10 VAS, worse at night affecting sleep, was associated with decreased range of motion in all planes, and weakness to the extent

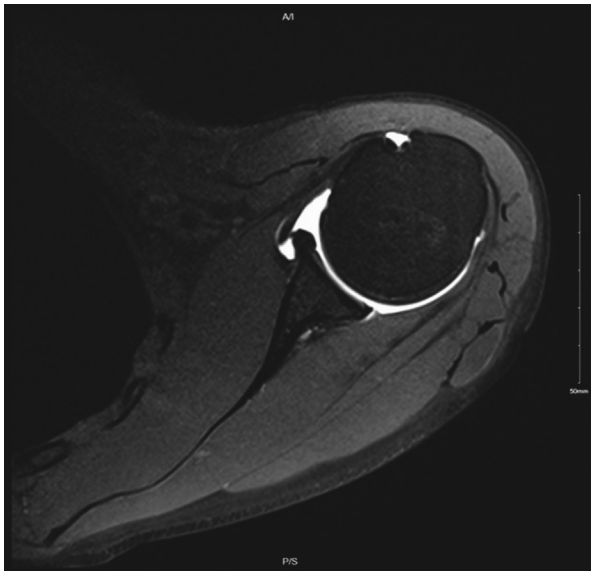


Figure 4 Repeat MRI left shoulder axial view T2 series demonstrating resolution of bony edema after completion of arthroscopic débridement and antibiotic management. MRI, magnetic resonance imaging.

it was difficult to remove a shirt. Initial SANE score at presentation was 20/100.

The patient first obtained an MRI after 8 months of persistent shoulder pain and weakness despite a small improvement around 4–5 months from injection followed by return and progression of symptoms. MRI revealed increased signal in the subacromial bursa without associated bony edema. Due to failure to improve after prolonged symptoms, arthroscopic irrigation and débridement with harvest of tissue biopsies from the subacromial space of the subacromial bursa harvested with a meniscal punch was performed 3 weeks following the MRI. Intraoperative cultures grew out *C. acnes* from the subacromial bursa specimens.

The patient was subsequently placed on 6 months of oral antibiotic therapy with amoxicillin and underwent extensive physical therapy. She currently reports a SANE score of 90/100. She reports persistent pain to the left shoulder, worse at night, continued difficulty sleeping on the effected left side, and limitations participating in home improvement projects involving overhead activities.

A comparison of cases and relevant details are included in [Table I](#) ([Table I](#)).

Discussion

It should be emphasized that vaccine administration is highly safe and effective.⁷ Thus, the risk of SIRVA is low and should not be a deterrent to receiving recommended vaccinations. Nonetheless, with increasing rates of vaccination and a global effort to obtain COVID-19 herd immunity through mass vaccination campaigns, physicians should be aware of the presentation and treatment of SIRVA as it is likely to become more prevalent with time. Arthroscopic shoulder and sports medicine surgeons may receive referrals for management of patients who are refractory to conservative management. Currently, there is no clearly agreed-upon management strategy for these patients when prolonged conservative management fails.

Diagnosis of SIRVA can be challenging for healthcare professionals as symptoms overlap with other more common shoulder pathology. The primary discriminating feature is

temporal proximity to intramuscular injection in patients without a history of prior shoulder dysfunction.⁸ As noted previously, the predominant treatment is supportive and conservative. After failure of conservative management, MRI imaging may reveal an increased signal in the subacromial bursa, intramuscular signal in the deltoid, or increased T2 signal in the greater tuberosity.¹³ Associated symptoms of stiffness, pain even at rest, night pain, and weakness overlaps with those of *C. acnes* infection.

We present a case series of 3 patients with refractory SIRVA who ultimately underwent arthroscopic management due to persistent pain and poor function. All cases had culture results positive for *C. acnes* and all responded, at least partially, to arthroscopic débridement and antibiotic therapy.

Since the presence of *C. acnes* has been identified by deep biopsies in both open and arthroscopic primary shoulder surgery in approximately 20% of cases, it is reasonable to consider the positive cultures in this case series represent contaminant and do not represent a clinically significant infection.^{6,12,14,17} Although a causal relationship cannot be established based on this limited series, the association may be relevant to treating physicians in forming a differential diagnosis.

Generally, positive cultures for *C. acnes* have been correlated to presence of skin colonization and male gender.⁵ By contrast, the patients in this series were all female. This difference may be incidental to females generally having thinner habitus and smaller deltoid muscle volume than men or due to other reasons not immediately apparent.¹ Additionally, other authors have similarly identified a “too high” position as a risk factor^{2,5,19} for SIRVA. In this series, all patients described a “high” position on the shoulder for vaccine administration, although this observation is limited by recall bias and lack of objective criteria to confirm the injection location site due to the time elapsed between injection and clinical presentation to a treating surgeon.

In a recent report of SIRVA after COVID-19 vaccination, the patient was also an elderly female with a thin body habitus.² The authors in the case report hypothesize poor vaccine technique, combined with smaller body habitus may increase risk of injection into the subacromial bursa or underlying bone. In this series, all patients fit a similar pattern.

This suggests a longer needle length combined with smaller body habitus and a proximal injection location may be risk factors for SIRVA due to injection into the subacromial bursa, into the rotator cuff tissue, or even into the greater tuberosity bone.

While the clinical significance of the positive cultures cannot be causally related to the patients’ symptoms in this series, the presence of improvement after arthroscopic débridement and antibiotic management lends credibility to an infectious etiology.

The location of the distal infraspinatus and teres minor tendons, their entheses, and the underlying bone has been previously reported as a common location for persistent shoulder pain after vaccination.^{4,15} This was a similar location in this series as identified on MRI images, suggesting the area of maximal signal intensity. The benefit and timing of follow-up MRI for evaluation of response to treatment cannot be recommended based on this limited series because follow-up MRI was not routinely performed.

Finally, the vaccine administered in each case in this series was different, suggesting factors related to administration technique and/or patient-related factors may be more important in the development of SIRVA than the contents of the vaccination.

[Table II](#) offers guidelines for consideration when evaluating refractory SIRVA cases ([Table II](#)).

Table I

Patient demographics for each presented case.

Question	Case 1	Case 2	Case 3
Demographics	36 yo female	27 yo female	33 yo female
BMI	19.2	22.9	22.5
Injection site	Left shoulder (nondominant)	Left shoulder (nondominant)	Left shoulder (dominant)
Injection provider	Primary care office	Primary care office	Urgent care
Injection placement	“High”	“High and posterior”	“High”
Vaccine	Influenza	TDaP	Influenza
Onset of symptoms	Immediate	12–24 h	Immediate
Fevers/Chills	No	Yes	No
Time to seeking medical care	14 d	8 d	4 d
MRI	Increased signal in bursa/tuberosity	Increased signal in bursa	Increased signal in bursa
Time to surgery	6 mo	1 mo	9 mo
Biopsy results	<i>C. acnes</i>	<i>C. acnes</i>	<i>C. acnes</i>
Antibiotic treatment	IV 6 weeks	IV 6 weeks	Oral × 6 mo
Final SANE rating	95–30 mo postop	75–16 mo postop	90–7 mo postop

BMI, body mass index, MRI, magnetic resonance imaging; SANE, single assessment numeric evaluation; IV, intravenous.

Table II

Proposed recommendations and key points.

- Patients presenting with atraumatic onset of shoulder pain, loss of function, and stiffness should be asked about recent vaccine administration.
- Primary management of presumed SIRVA should be conservative.
- Thinner patients may be at higher risk for refractory SIRVA.
- Advanced imaging with MRI or US may identify synovitis, subacromial bursitis, or edema within the greater tuberosity correlating to the injection site.
- When prolonged conservative management fails, arthroscopic débridement and harvest of deep tissue biopsies for culture can be considered.
- Cultures should be obtained from 3 distinct sites within the shoulder and held for a minimum of 14 d (ideally 21 d).
- Treatment of positive cultures should involve an informed discussion between the patient and a multidisciplinary team including infectious disease specialists to weigh the risk and benefit of potential treatment options.

SIRVA, shoulder injury related to vaccine administration; MRI, magnetic resonance imaging; US, ultrasound.

Conclusion

Based on available case reports and limited data, surgeons may consider the possibility of *C. acnes* positivity in the workup and treatment of persistent shoulder pain after vaccine administration. A history of small body habitus, high injection site location, pain at rest or with sleep, and loss of shoulder motion and strength should raise an index of suspicion for advanced imaging and, in select cases, arthroscopy with harvest of tissue cultures and concomitant arthroscopic débridement.

Disclaimers:

Funding: No funding was disclosed by the authors.

Conflicts of interest: Brian B Gilmer, MD, FABOS: Dr. Gilmer receives consulting fees from Arthrex, honoraria from Doximity, Industry support from Arthrex, Stryker, Smith and Nephew, DonJoy, and Ossur, Mammoth Hospital. He is on the advisory board for Smart Medical Devices. He participates on committees with AANA and Arthroscopy Journal. Dan Guttmann, MD: Dr. Guttmann receives grants from Arthrex, Medacta, Stryker, Smith and Nephew, DonJoy, and Breg. He also receives consulting fees from Arthrex. The other authors, their immediate families, and any research foundation with which they are affiliated have not received any financial payments or other benefits from any commercial entity related to the subject of this article.

References

1. Arias LM, Fadrique RS, Gil MS, Salgueiro-Vazquez ME. Risk of bursitis and other injuries and dysfunctions of the shoulder following vaccinations. *Vaccine* 2017;35:4870–6. <https://doi.org/10.1016/j.vaccine.2017.07.055>.
2. Atanasoff S, Ryan T, Lightfoot R, Johann-Liang R. Shoulder injury related to vaccine administration (SIRVA). *Vaccine* 2010;28:8049–52. <https://doi.org/10.1016/j.vaccine.2010.10.005>.
3. Bodor M, Montalvo E. Vaccination-related shoulder dysfunction. *Vaccine* 2007;25:585–7. <https://doi.org/10.1016/j.vaccine.2006.08.034>.
4. Bodor M, Uribe Y, Srikumaran U. Ultrasonic aspiration for vaccination-related shoulder dysfunction. *Heliyon* 2021;7:e08442. <https://doi.org/10.1016/j.heliyon.2021.e08442>.
5. Cantarelli Rodrigues T, Hidalgo PF, Skaf AY, Serfaty A. Subacromial-subdeltoid bursitis following COVID-19 vaccination: a case of shoulder injury related to vaccine administration (SIRVA). *Skeletal Radiol* 2021;50:2293–7. <https://doi.org/10.1007/s00256-021-03803-x>.
6. Chuang MJ, Jancosko JJ, Mendoza V, Nottage WM. The incidence of Propionibacterium acnes in shoulder arthroscopy. *Arthroscopy* 2015;31:1702–7. <https://doi.org/10.1016/j.arthro.2015.01.029>.
7. Duclos P. A global perspective on vaccine safety. *Vaccine* 2004;22:2059–63. <https://doi.org/10.1016/j.vaccine.2004.01.010>.
8. Floyd MW, Boyce BM, Castellan RM, McDonough EB. Pseudoseptic arthritis of the shoulder following pneumococcal vaccination. *Orthopedics* 2012;35:e101–3. <https://doi.org/10.3928/01477447-20111122-31>.
9. Hexter AT, Gee E, Sandher D. Management of glenohumeral synovitis secondary to influenza vaccination. *Shoulder Elbow* 2015;7:100–3. <https://doi.org/10.1177/1758573214560258>.
10. Hirsiger JR, Tamborrini G, Harder D, Bantug GR, Hoenger G, Recher M, et al. Chronic inflammation and extracellular matrix-specific autoimmunity following inadvertent periarticular influenza vaccination. *J Autoimmun* 2021;124:102714. <https://doi.org/10.1016/j.jaut.2021.102714>.
11. Macomb CV, Evans MO, Dockstater JE, Montgomery JR, Beakes DE. Treating SIRVA early with corticosteroid injections: a case series. *Mil Med* 2020;185:e298–300. <https://doi.org/10.1093/milmed/usz269>.
12. Mook WR, Klement MR, Green CL, Hazen KC, Garrigues GE. The incidence of Propionibacterium acnes in open shoulder surgery: a controlled diagnostic study. *J Bone Joint Surg Am* 2015;97:957–63. <https://doi.org/10.2106/JBJS.N.00784>.
13. Okur G, Chaney KA, Lomasney LM. Magnetic resonance imaging of abnormal shoulder pain following influenza vaccination. *Skeletal Radiol* 2014;43:1325–31. <https://doi.org/10.1007/s00256-014-1875-9>.
14. Patzer T, Petersdorf S, Krauspe R, Verde PE, Henrich B, Hufeland M. Prevalence of Propionibacterium acnes in the glenohumeral compared with the subacromial space in primary shoulder arthroscopies. *J Shoulder Elbow Surg* 2018;27:771–6. <https://doi.org/10.1016/j.jse.2017.10.039>.
15. Taylor BC, Hinke D. Shoulder injury related to vaccine administration (SIRVA). *Appl Radiol* 2014;43:30–2.

16. Uchida S, Sakai A, Nakamura T. Subacromial bursitis following human papilloma virus vaccine misinjection. *Vaccine* 2012;31:27-30. <https://doi.org/10.1016/j.vaccine.2012.10.075>.
17. Warne WJ, Hsu JE. Definition of a “True” Periprosthetic Shoulder Infection Still Eludes Us: Commentary on an article by Salvatore J. Frangiamore, MD, et al.: “Early Versus Late Culture Growth of: *Propionibacterium acnes*: in Revision Shoulder Arthroplasty”. *J Bone Joint Surg Am* 2015;97:e56. <https://doi.org/10.2106/JBJS.O.00516>.
18. Wong W, Okafor C, Belay E, Klifto CS, Anakwenze O. Arthroscopic surgical management of shoulder secondary to shoulder injury related to vaccine administration (SIRVA): a case report. *J Shoulder Elbow Surg* 2021;30:e334-7. <https://doi.org/10.1016/j.jse.2021.01.027>.
19. Yuen WL, Loh YJ, Wang DB. SIRVA (Shoulder Injury Related to Vaccine Administration) following mRNA COVID-19 Vaccination: Case discussion and literature review. *Vaccine* 2022;40:2546-50. <https://doi.org/10.1016/j.vaccine.2022.03.037>.